

# Detection of Optic Disk and Fovea of Fundus Retinal Image Using Morphological operations and FCM

S.M.Ramya<sup>1</sup>, G.Jayanthi<sup>2</sup>

PG student Parisutham Institute of Technology and Science, Thanjavur, Tamilnadu, India<sup>1</sup>.

(Email: smramyatvr@gmail.com)

Asst. Prof/ECE Dept, Parisutham Institute of Technology and Science, Thanjavur, Tamilnadu<sup>2</sup>.

**Abstract:** Analysis of medical images is one of the crucial topics in medical image processing to detect the diseases and to check the status of the abnormality. Specifically, localization of Optic Disk and fovea center is a substantial problem in ophthalmic image processing research area. This paper presents an efficient method using morphological techniques and Fuzzy C-means clustering (FCM) to detect Optic Disk (OD) and fovea center respectively. Here, we take the input images as green channel of RGB fundus retinal images which are resized to reduce the computational time of processing. Resized images are preprocessed to remove noise and morphological operations are applied to obtain the brightest part i.e OD. Fovea can be localized using the combined effect of sliding window and Fuzzy C-means Clustering techniques.

**Keywords-** Morphological operations, Fuzzy C-Means clustering (FCM), optic disk (OD), fovea, sliding window techniques

## I. INTRODUCTION

Diabetic retinopathy (DR) is the commonest complication of diabetes and is one of the leading causes of blindness. Therefore, early detection of retinopathy is an essential part of diabetes care. In the eye, Optic disk and fovea center are the two vital parts of eye that shows the status of diabetes.

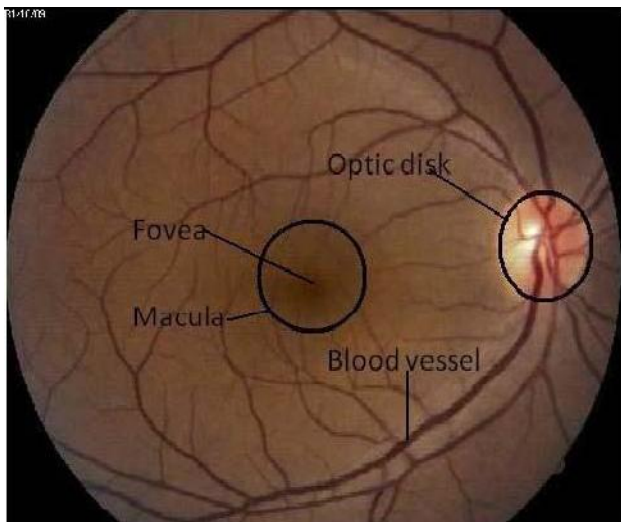


Fig 1: Retinal Fundus Image

The optic disc represents the beginning of the optic nerve and is the point where the axons of retinal ganglion cells come together. The optic disc is also the entry point for major blood vessels that supply blood to the retina. There are no light sensitive rods or cones to respond to a light stimulus at this point. This causes a break in the visual field called "the blind spot". A pale disc is an optic disc which varies in color from a pale pink or orange color to white. A pale disc is an indication of a disease condition.

The fovea is located in the center of the macula region of the retina. It is responsible for sharp central vision (also known as foveal vision), which is necessary for humans to read, drive, and any activity where visual detail is of primary importance. Fovea size is relatively small when compared to the rest of retina, but the fovea is very important for seeing fine detail and color. Usually this fovea zone is approximated to a circle of diameter 400 micron. The central region called the macula is a circular area measuring about 4 to 5mm in diameter. A small depression in the centre of the macula is called fovea.

The fundus images are most commonly used by ophthalmologists to monitor the severity of disease. They are captured using devices called ophthalmoscopes. Normally these images are manually graded by specially trained clinician which is a time consuming and resource intensive process. A typical retinal fundus image with its features labeled is shown in figure 1.

## II RELATED WORKS

### *A. Optic Disc Segmentation Based On Watershed Transform*

PCA is applied on the RGB fundus image in order to obtain a grey image in which the different structures of the retina, such as vessels and OD, are differentiated more clearly to get a more accurate detection of the OD. Then, the vessels are removed through morphology technique to make the segmentation task easier. Variant of the watershed transformation, the stochastic watershed transformation, followed to a stratified watershed, are implemented on a region of the original image. Finally, it must be discriminated which of the obtained watershed regions belong to the optic disc and which ones are not. A geodesic transformation and a further threshold are used to achieve that purpose.

The algorithm is fully automatic, so process is speeded up and user intervention is avoided. Moreover, the method provides robustness in each processing step. i.) It is independent of the database used. ii.) It employs the grey-image centroid as initial seed so that not only the pixel intensity is taken into account. iii.) It makes use of the stochastic watershed in order to avoid sub-segmentation problems

The real watershed transform of a gradient represent many catchment basins. Each catchment basin corresponds to a minimum of the gradient. These minima are produced by small variations, mainly due to noise, in the grey values.

### *B. Segmentation of Blood Vessels and Optic Disc in Retinal Images*

This method initially extracts the retina vascular tree using the graph cut technique. The blood vessel information is then used to estimate the location of the optic disc. The optic disc segmentation is performed using two alternative methods. i.) Markov Random Field (MRF) image reconstruction method and ii.) Compensation Factor method

Markov Random Field (MRF) image reconstruction method: The objective of the algorithm is to find a best match for some missing pixels in the image, however one of the weaknesses of MRF based reconstruction is the requirement of intensive computation. To overcome this problem, we have limited the reconstruction to the region of interest (ROI) and using prior segmented retina vascular tree, the reconstruction was performed in the ROI.

Compensation factor method: It incorporates the blood vessels into the graph cut formulation by introducing a compensation factor  $V_{ad}$ . This factor is derived using prior information of blood vessel. The segmentation of the disc is affected by the value of  $V_{ad}$ , the method achieves poor segmentation results for low value of  $V_{ad}$ . However when the value of the  $V_{ad}$  increases, the performance improves until the value of  $V_{ad}$  is high enough to segment the rest of the vessels as foreground.

### *C. Automatic detection of optic disc based on PCA and stochastic watershed*

An automatic method to detect the optic disc is presented. It is focused on using stochastic watershed transformation on a fundus image to obtain the optic disc contour. Pre-processing of the original RGB image is required.

Pre-processing consists of applying PCA to transform the input image to grey scale. This technique combines the most significant information of the three components RGB in a single image so that it is a more appropriate input to the segmentation method. Mathematical morphology is a non-linear image processing methodology based on minimum and maximum operations whose aim is to extract relevant structures of an image. Watershed transformation algorithm is a powerful segmentation method whenever the minima of the image represent the objects of interest and the maxima are the separation boundaries between objects. Due to this fact, the input image of this method is usually a gradient image. Once the region of interest has been obtained by the watershed transformation, the result must be adjusted to eliminate false contours, which are detected due generally to the blood vessels that pass through the OD. A final OD approximation is usually done through ellipses or circles. The fit is performed by means of Kasa's method which lets calculate the center and the radius of the circle that better is adapted to a binary region through least squares.

In statistics, PCA is a method for simplifying a multidimensional dataset to lower dimensions for analysis, visualization or data compression. The price to be paid for PCA's flexibility is in higher computational requirements as compared to, e.g., the fast Fourier transform

### *D. An automatic screening method to detect Optic disc in the retina*

OD detection helps the ophthalmologists to find whether the patient is affected by diabetic retinopathy or not. The proposed technique is to use line operator which gives higher percentage of detection than the already existing methods.

The method starts with converting the RGB image input into its LAB component. (The technique makes use of the circular brightness structure of the OD, the lightness component of a retinal image is first extracted. We use the lightness component within the LAB color space, where the OD detection usually performs the best). This image is smoothed using bilateral smoothing filter. (A bilateral filter is a non-linear, edge-preserving and noise-reducing smoothing filter for images. The intensity value at each pixel in an image is replaced by a weighted average of intensity values from nearby pixel). Filtering is carried out using line operator (to detect circular regions that have similar brightness structures as OD). After which gray orientation and binary map orientation is carried out and then with the use of the resulting maximum image variation the area of the presence of the OD is found. The portions other than OD are blurred using 2D circular convolution. On applying mathematical steps like peak classification, concentric circles design and image difference calculation, OD is detected.

The bilateral filter in its direct form can introduce several types of image artifacts:

- Staircase effect - intensity plateaus that lead to images appearing like cartoons
- Gradient reversal - introduction of false edges in the image

## II. PROPOSED SYSTEM

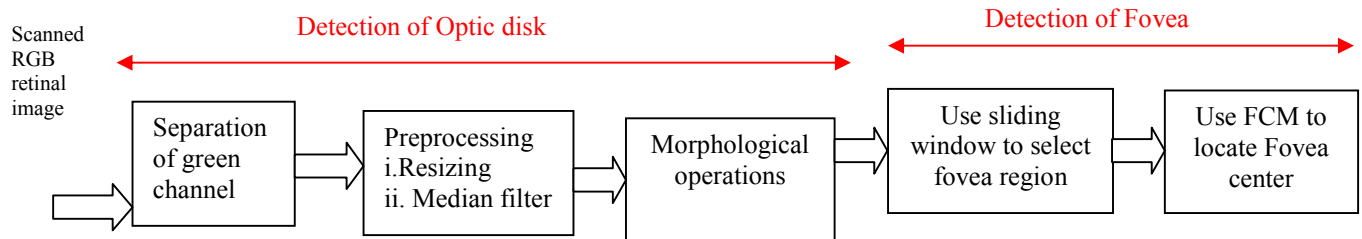


Figure 2: Block diagram of Proposed system

### A. Detection of OD:

#### i. Separation of green channel

The optic disc and fovea center are most prominent in the green layer of the intensity image of retina and the blood vessels can be easily identified in the green layer of the retinal images. Therefore, the input images are green channels of intensity images.

An RGB image, sometimes referred to as a truecolor image, is stored as an  $m$ -by- $n$ -by-3 data array that defines red, green, and blue color components for each individual pixel. RGB images do not use a palette. The color of each

pixel is determined by the combination of the red, green, and blue intensities stored in each color plane at the pixel's location. Graphics file formats store RGB images as 24-bit images, where the red, green, and blue components are 8 bits each. The three color components for each pixel are stored along the third dimension of the data array. For example, the red, green, and blue color components of the pixel (10,5) are stored in RGB(10,5,1), RGB(10,5,2), and RGB(10,5,3), respectively.

#### ii.) Preprocessing

Resizing: To standardize the retinal size, all input images are resized to have a retinal diameter,  $D_{FOV}$  (Field of View) of 300 pixels. Thus, a drastic reduction in computational time is provided.

Median filter: An original RGB retinal image is processed in pre-processing stage. A median filter is applied to the image to remove some noises (noisy pixels as outliers) which came from digital fundus camera or some other sources.

Median filter helps us by erasing the black dots, called the Pepper, and it also fills in white holes in the image, called Salt " impulse noise "It's like the mean filter but is better in 1-Preserving sharp edges 2-The median value is much like neighborhood pixels and will not affect the other pixels significantly -this means that the mean does that.

iii. morphological operations. The OD may be distinguished in eye fundus images as a rounded shape having high intensity values (see Fig. 1). In order to locate OD exploiting these features, a morphological processing is performed to obtain a smoothed image where the largest bright region is enhanced. Specifically, a set of morphological opening and closing operations are iteratively applied four times to green channel of retinal image.

#### Opening:

The opening of an image  $f$  by a structuring element  $s$  (denoted by  $f \circ s$ ) is an erosion followed by a

dilation. Opening is so called because it can open up a gap between objects connected by a thin bridge of pixels

The basic effect of an opening is somewhat like erosion in that it tends to remove some of the foreground (bright) pixels from the edges of regions of foreground pixels.

However it is less destructive than erosion in general. As with other morphological operators, the exact operation is determined by a structuring element. The effect of the operator is to preserve foreground regions that have a similar shape to this structuring element, or that can completely contain the structuring element, while eliminating all other regions of foreground pixels.

*Closing:*

The closing of an image  $f$  by a structuring element  $s$  (denoted by  $f \bullet s$ ) is a dilation followed by an erosion Closing is so called because it can fill holes in the regions while keeping the initial region sizes.

Closing is similar in some ways to dilation in that it tends to enlarge the boundaries of foreground (bright) regions in an image (and shrink background color holes in such regions), but it is less destructive of the original boundary shape. As with other morphological operators, the exact operation is determined by a structuring element. The effect of the operator is to preserve background regions that have a similar shape to this structuring element, or that can completely contain the structuring element, while eliminating all other regions of background pixels.

The combination of opening and closing operations provides the brighter region that is OD. The selected structural element is a disk whose radius  $r$  increases in each iteration ( $r = 2; 4; 6; 8$ ). Small bright structures that may appear in the fundus image (i.e., hard exudates), are progressively removed. The brightest region can be assumed to be belonging to OD region. Thus, the pixels with the highest intensity are selected as potential OD pixel candidates. The OD is finally located through the centroid of this set of pixels.

*B. Detection of fovea:*

We use Fuzzy C-means clustering as a technique for the detection of Fovea where each data point belongs to more than one class.

Once the center and boundary of the OD is found the diameter ( $d$ ) of the optic disk is found. And then a point Q is located at a distance  $2.5 * d$  from the optic disk center towards the left if OD center is in the right side and towards the right if OD center is in the left side. Fovea is localized by using sliding window technique and Fuzzy C means Clustering algorithm.

Sliding window of small size at the point Q is taken and a small region belonging to the fovea region is identified. The features such as intensity value, orientation, spatial connectivity etc of each pixel that are inside the window are extracted and a feature set is formed. FCM is applied to the feature set to separate the fovea pixels. The centroid of the fovea pixels represents the fovea center. The accuracy and complexity of FCM increases with the number of features selected. Hence there is a tradeoff exists between complexity and accuracy of separation. Here, features such as orientation and spatial connectivity are used.

This algorithm works by assigning membership to each data point corresponding to each cluster center on the basis of distance between the cluster center and the data point. More the data is near to the cluster center more is its membership towards the particular cluster center. Clearly, summation of membership of each data point should be equal to one. After every iteration, membership and cluster centers are updated according to the formulae given below.

*Fuzzy C means Clustering Algorithm:*

1 → Initialize  $U=[u_{ij}]$  matrix,  $U^{(0)}$

2 → From the partition matrix, generate centroid for each cluster

$$C_j = \frac{\sum_{[i = 1 \text{ to } N]} U_{ij}^m \cdot X_i}{\sum_{[i = 1 \text{ to } N]} U_{ij}^m}$$

$m \rightarrow$  expo whose value must be greater than 1. By adjusting the value of  $m$ , error can be minimized, where error(obj.fn) is the difference between the two successive partition matrix.

3 → Update  $U^{(k)}, U^{(k+1)}$

$$U_{ij} = \frac{1}{\sum_{(k = 1 \text{ to } C)} \left[ \frac{|X_i - C_j|}{|X_i - C_k|} \right]^{\frac{2}{m-1}}}$$

4 → If  $\|U^{(k+1)} - U^{(k)}\| < \epsilon$  then STOP; otherwise return to step 2.

In our program,  $\epsilon$  is used as min\_impro, which is equal to  $1e^{-8}$ . Smaller the value of  $\epsilon$ , higher the accuracy.

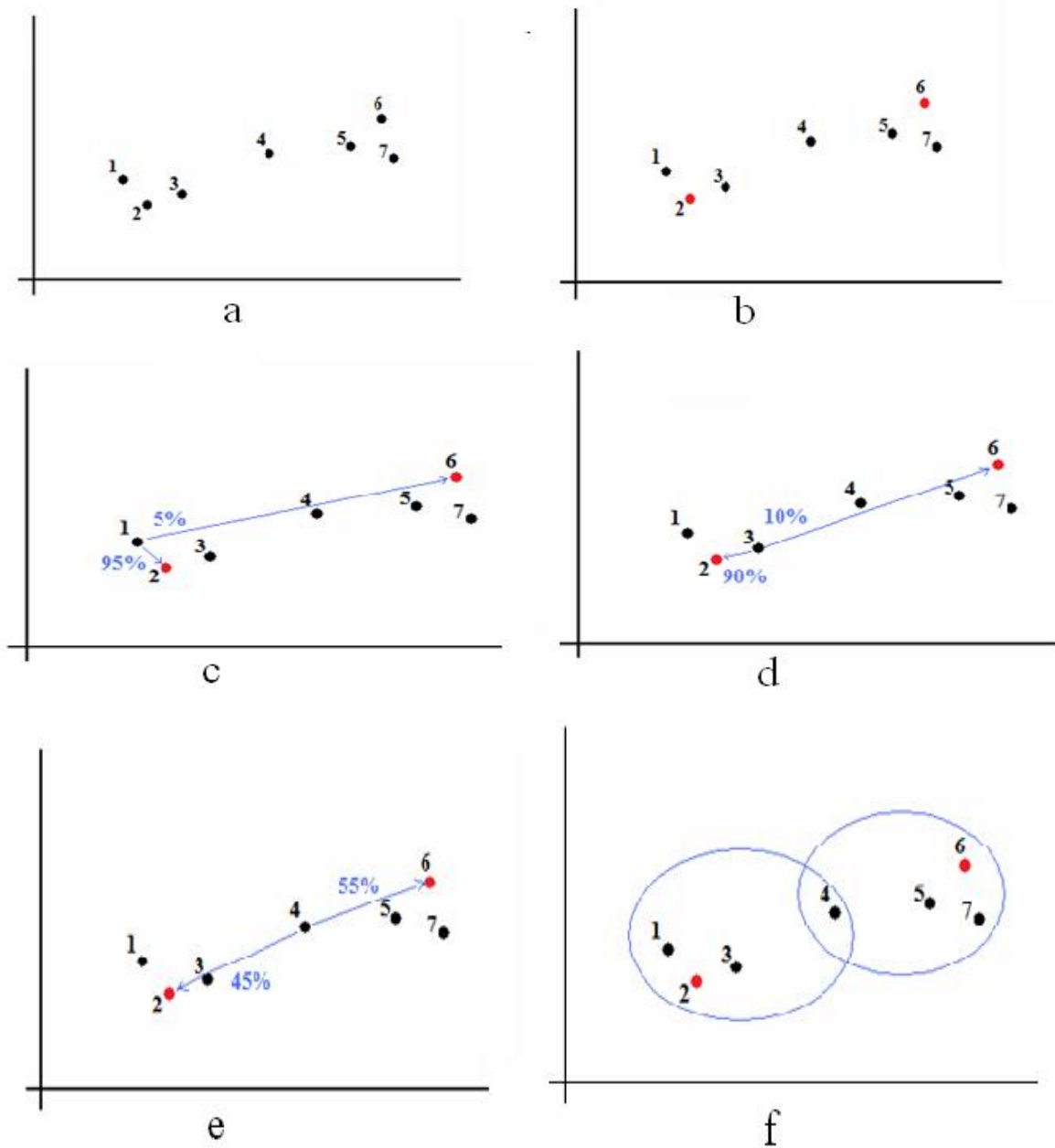


Figure 3: (a-f) Process of Fuzzy C-means clustering

#### IV. RESULTS AND DISCUSSION

##### A. Test Measures:

Three selected metrics are applied to evaluate quantitatively the performance of proposed system: True Positive Rate, False Positive Rate (FPR), and Accuracy (Accu). In the scope of information retrieval, a contingency table that involves the true positives (TP), true negatives (TN), false positives (FP) and false negatives (FN) is given below.

Actual	Predicted	
	Positive	Negative
Positive	True positive (TP)	False negative (FN)
Negative	False positive (FP)	True negative (TN)

Table 1: Confusion matrix representation

Some pixels belong to OD region and are tested as OD pixels. They are called true positives(TP). Some pixels are OD pixels, but the test claims they don't. They are called false negatives(FN). Some are not belong to OD region, and the test says they don't - true negatives(TN). Finally, some pixels are non-OD pixels but the test says they belong. They are called as false positives (FP).Thus, the number of true positives, false negatives, true negatives, and false positives add up to 100% of the set.

*True Positive Rate:*

It is also known as recall, is the proportion of pixels that tested positive (TP) of all the pixels that actually are positive (TP+FN). It can be seen as the probability that the test is positive given that the pixel is non-OD pixel. With higher sensitivity, fewer actual cases of pixels go undetected.

*False Positive Rate:*

The calculation involves also false positive values (i.e., FPs), but the FP values indicate only the number of non-OD region pixels that are incorrectly identified as OD region pixels. Hence, FPR is the number of negative instances (i.e., non-OD pixels) that were erroneously reported as being positive (i.e., OD pixels).

*Accuracy:*

Accuracy measures the fraction of all instances that are correctly categorized. It is the ratio of the number of correct classifications to the total number of correct or incorrect classifications.

$$TPR = \frac{|TP|}{|TP|+|FN|}$$

$$FPR = \frac{|FP|}{|FP|+|TN|}$$

$$Accuracy = \frac{|TP|+|TN|}{|TP|+|FP|+|TN|+|FN|}$$

*ROC Plot and ROC Area:*

- Developed to statistically model false positive and false negative detections of radar operators
- Better statistical foundations than most other measures
- Standard measure in medicine and biology

**Properties of ROC**

- ROC Area:
  - 1.0: perfect prediction
  - 0.9: excellent prediction
  - 0.8: good prediction
  - 0.7: mediocre prediction

- 0.6: poor prediction
- 0.5: random prediction
- <0.5: something wrong!
- Slope is non-increasing
- Each point on ROC represents different tradeoff (cost ratio) between false positives and false negatives
- Slope of line tangent to curve defines the cost ratio
- ROC Area represents performance averaged over all possible cost ratios
- If two ROC curves do not intersect, one method dominates the other
- If two ROC curves intersect, one method is better for some cost ratios, and other method is better for other cost ratios.

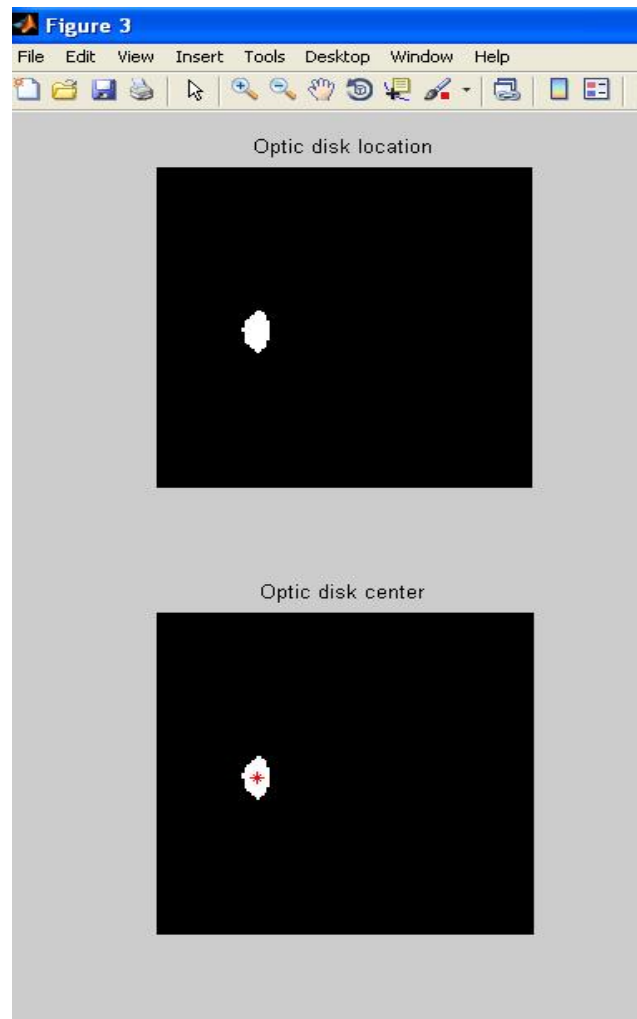


Figure 4: Location of optic disk

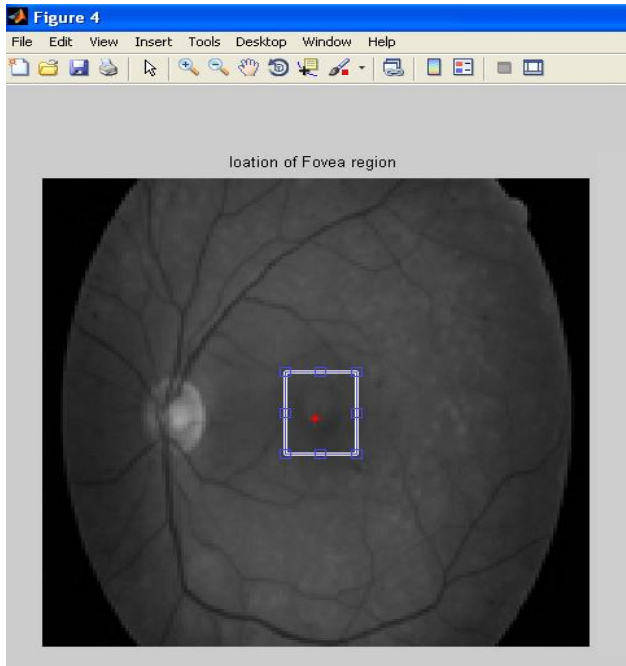


Figure 5: Selection of Fovea region

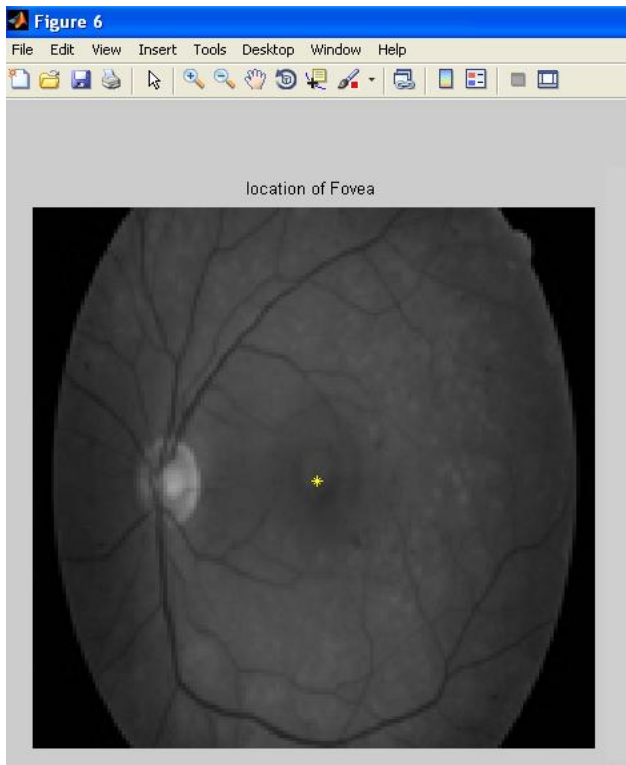


Figure 6: Location of fovea

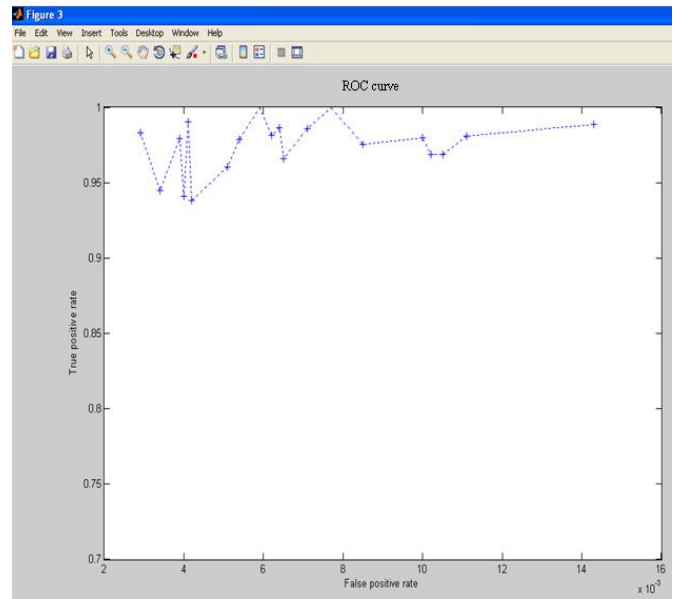


Figure 7 : ROC curve

#### IV. CONCLUSION

This project analyses the method to detect the Optic disk and fovea region of the eye. It performs well on individuals own data set consisting of images with variation. This method is robust also. This proposed methodology can be utilized in hospitals to detect diseases occurring on the eyes by doctors easily. Future scope of this project is to detect many eye diseases thus making mankind to be benefitted in large extent to be free from eye diseases leading to blindness with higher efficiency.

#### ACKNOWLEDGEMENT

I would like to thank my guide Mrs.G.Jayanthi Asst. Prof., Electronics and communication engineering Department, Parisutham Institute of Technology and Science, Thanjavur for her help and guidance to enable us to propose this system.

#### REFERENCES

- [1] Amandeep Kaur\* and Reecha Sharma “Optic Disc Segmentation Based On Watershed Transform” International Journal of Advanced Research in Computer Science & Software Engineering (2014) <http://www.ijarcse.com>
- [2] Ana Salazar-Gonzalez, Djibril Kaba, Yongmin Li and Xiaohui Liu, “Segmentation of Blood Vessels and Optic Disc in Retinal Images” IEEE Journal of Biomedical and Health Informatics,2014

- [3] K.Kavitha, M.Malathi “Optic Disc and Optic Cup Segmentation for Glaucoma Classification” International Journal of Advanced Research in Computer Science & Technology (IJARCST 2014)
- [4] Murugan.R1 , Dr.Reeba Korah 2 “ An automatic screening method to detect Optic disc in the retina” International Journal of Advanced Information Technology (IJAIT),2012
- [5] Rashid Jalal Qureshi, Laszlo Kovacs, Brigitta Nagy Balazs Harangi, Andras Hajdu “Automatic Detection of the Fovea and Optic Disk in Digital Retinal Images by Combining Algorithms”
- [6] Sandra Morales, Valery Naranjo, David Perez, Amparo Navea, Mariano Alcaniz “Automatic detection of optic disc based on PCA and stochastic watershed” European Signal Processing Conference,2012
- [7] Soumitra Samanta, Sanjoy Kumar Saha and Bhabatosh Chanda “A Simple and Fast Algorithm to Detect the Fovea Region in Fundus Retinal Image”
- [8] Thomas Fuhrmann and Andreas Uh “Doubts about the Usefulness of Retina Codes in Biometric Recognition”
- [9] Varalekshmi .V.R, P.Janardhanan. “Detection of fovea region in fundus retinal image using wavelet transform and fuzzy c-means clustering”
- [10] Yu\*a,b, S Barrigab, C Agurtoa,b, S Echegarayb, M Pattichisa, G Zamorab, W Baumanc and P Solizb “Fast Localization of Optic Disc and Fovea in Retinal Images for Eye Disease Screening”

#### **BIOGRAPHY**

S.M.RAMYA<sup>1</sup> received degree B.E (ECE) from Anjalai Ammal Mahalingam Engineering College, Tiruvarur, Tamilnadu, India, affiliated to Anna University Chennai in 2013. She is currently persuing M.E – Communication Systems in Parisutham Institute of Technology and Science, Thanjavur, Tamilnadu, India, (affiliated to Anna University Chennai).